



Research paper

First ocular report of *Gurltia paralyans* (Wolffhügel, 1933) in cat

Raquel Udiz-Rodríguez^a, Katherine Garcia-Livia^b, Maria Valladares-Salmerón^c,
 Maria Naira Dorta-Almenar^a, Natalia Martín-Carrillo^b, Aaron Martín-Alonso^b,
 Elena Izquierdo-Rodríguez^b, Carlos Feliu^d, Basilio Valladares^b, Pilar Foronda^{b,*}

^a Centro de Referencia en Oftalmología animal Visión Veterinaria, Avda. de los Majuelos, 93, Tenerife, 38108, Spain

^b Instituto Universitario de Enfermedades Tropicales y Salud Pública de Canarias, Universidad de La Laguna, Avda. Astrofísico F Sanchez s/n, Tenerife, 38203, Spain

^c Laboratorio Finca España. Avenida Las Palmeras, Tenerife, 38205, Spain

^d Secció de Parasitologia, Departament de Biologia, Sanitat i Medi Ambient, Facultat de Farmàcia i Ciències de l'Alimentació, Universitat de Barcelona, Barcelona, 08028, Spain



ARTICLE INFO

Keywords:

Gurltia paralyans
 Ocular parasite
 Cat
 Spain

ABSTRACT

A two-year-old cat from Tenerife, Canary Islands (Spain), presented with two months history of uveitis in the left eye. It had been treated for two months but still showed an active uveitis. After new treatment, eye examination showed a mobile worm in the anterior chamber. Following surgical removal, the worm was obtained. Morphological study revealed that it was a male metastrongyloid nematode (Nematoda: Metastrongyloidea) with caudal bursa and two similar spicules. Molecular tools based on the 18S rRNA gene sequence identified the parasite as *Gurltia paralyans*, which is a neurotropic nematode previously found in South America. Therefore, this article describes the first report of ophthalmic case of parasitism by *G. paralyans*, and cites for first time this species out of South America.

1. Introduction

Ocular parasitoses by worms in domestic cats are uncommon, although some parasites have been reported: *Thelazia californiensis* (Otranto and Traversa, 2005), *Thelazia callipaeda* (Motta et al., 2014), *Onchocerca lupi* (Labelle et al., 2011) and larval myiasis (*Cuterebra*) (Harris et al., 2000), among others. *Thelazia callipaeda* is a whitish nematode infesting the conjunctival pouches and the lachrymal ducts of dogs, cats, rabbits, wild carnivores and humans (Anderson, 2000). In the case of *T. californiensis*, the pathogenesis is still unknown (Bowman et al., 2002). *Onchocerca lupi* in dogs causes ocular lesions of various degrees, but in cats the specific pathology is not properly described (Labelle et al., 2011). *Cuterebra* larval migration is proposed to be a potential cause of feline ischemic encephalopathy and feline seizure disorders (Glass et al., 1998; Williams et al., 1998).

The aim of the present study was to identify a worm affecting the eye of a domestic cat in Tenerife, Canary Islands, Spain.

2. Material and methods

2.1. Animal

A two-year-old cat, which had been rescued from feral one year ago,

was presented to “Centro de Referencia en Oftalmología animal Visión Veterinaria” in Tenerife, Canary Islands (Spain). It was not possible to find out any information about the previous provenance or travels of this cat. It had a two months history of uveitis in the left eye, treated with tobramycin/dexamethasone (Tobradex®, Alcon Cusi) three times a day for one month, and the result was favorable. However, it still showed exudative uveitis with fibrin in the anterior chamber, posterior synechiae and incipient cataracts, similar to chronic uveitis in active phase. The hemogram, biochemical (cholesterol, alkaline phosphatase, gamma glutamil transpeptidase, amylase, glucose, triglycerides, creatinine, blood urea nitrogen, phosphorus, lipase, aspartate aminotransferase, alanine aminotransferase, Bilirubin and Bilirubin Fractions, calcium), proteinogram and immunoglobulins G, A, and M analyses showed normal values except for eosinophilia and a light increase of alkaline phosphatase. Serology was negative for leukemia, immunodeficiency, coronavirus, panleucopenia and calicivirus.

2.2. Procedures

The cat was treated with bromfenac 0.9 mg/ml (Yellox colirio® Bausch + Lomb), tropicamide 10 mg/ml (Colircusi tropicamida® Alcon cusi), Ciprofloxacin 3 mg/ml (Oftacilox colirio®, Alcon cusi), prednisolone acetate 1% (Pred forte colirio® Allergan), artificial tears of

* Corresponding author.

E-mail address: pforonda@ull.edu.es (P. Foronda).



Fig. 1. High angle view of *Gurltia parvalysans* adhered with fibrin to the anterior chamber of the lens.

sodium hyaluronate 2 mg/ml (Hylo gel® Brill Pharma) thrice/day, and orally with 25 mg/kg of clindamycin (Zodon® Ceva laboratories) twice/day and 0.1 mg/kg of meloxicam (Metacam 0.5 mg/ml Boehringer Ingelheim) once/day. Clinical evolution was favorable, but fibrin deposits remained in the anterior chamber.

2.3. Sample collection

After 5 weeks, a moving worm adhered with fibrin to the anterior chamber of the lens was detected (Fig. 1; video 1).

The cat was anesthetized for the parasite extraction. An intraocular access was carried out by corneal incision in the dorsal side quadrant with a 3 mm knife. A viscoelastic solution of 1.4% sodium hyaluronate (Hanax® Dioptrix) was applied to maintain the stability of the anterior chamber and paralyze the parasite. The extraction was carried out by means of ocular tweezers (video 2). For the worm identification, anterior and posterior ends were fixed and preserved in 70% ethanol and the middle part in absolute ethanol. Both ends were cleared in lactophenol solution for morphological study, data of the spicules length of *Oslerus rostratus* (almost 100 µm), *Aelurostrongylus abstrusus* (~200 µm or less), *Troglostrongylus* spp. (~600 µm) (Brianti et al., 2014) and *Gurltia parvalysans* (650–816 µm) (Muñoz et al., 2017) were used for the morphological identification. The middle part of the nematode was used for molecular analysis.

2.4. DNA isolation

The middle part of the worm was homogenized in 250 µl of a solution containing 30 mM Tris-HCl (pH 8.0), 10 mM EDTA and 0.4% SDS. Then, 3 µl of proteinase K (20 mg ml⁻¹) were added to the sample and then incubated at 56 °C overnight. After having inactivated the proteinase K, DNA extraction continued by following the method used by López et al. (2015). DNA was quantified using a spectrophotometer Nanodrop ND-1000 (Thermo Scientific, USA), and was stored at -20 °C until further processing.

2.5. PCR amplification

A 1708 bp region of the 18S ribosomal RNA (rRNA) gene was amplified using the primers NC18SF1 (5'-AAAGATTAAGCCATGCA-3') and NC5BR (5'-GCAGGTT CACCTACAGAT-3') as previously described Brianti et al. (2012). Approximately 50 ng of genomic DNA were added to each PCR. The 18S rRNA fragment was amplified using the following conditions: 95 °C for 10 min (first polymerase activation and denaturation); followed by 30 cycles of 94 °C for 30 s (denaturation), 57 °C

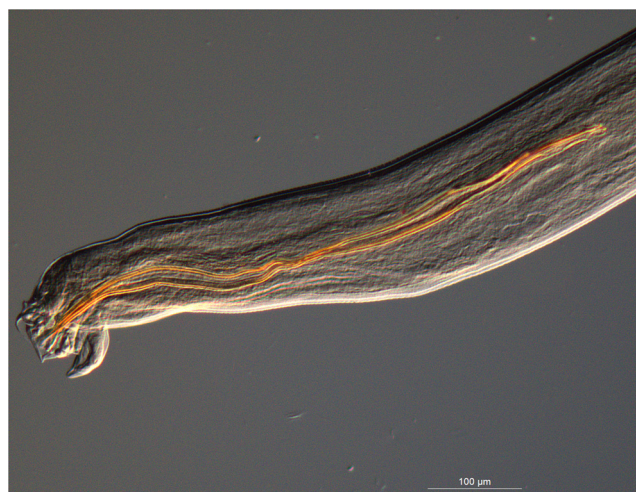

Fig. 2. Caudal end of *Gurltia parvalysans* showing the bursa and the spicules.

for 30 s (annealing), and 72 °C for 1 min and 45 s (extension); and a final extension at 72 °C for 7 min.

All amplicons were resolved on 2% agarose gels. The products were sequenced in Macrogen, Korea. To elucidate any homologies or similarities previously published in GenBank, a BLAST search was carried out.

Phylogenetic analysis based on Bayesian inference (BI) was carried out by using MrBayes. The model with the lowest Bayesian information criteria (BIC) value, which was calculated using jModelTest 2.1.10 (Darriba et al., 2012), was considered to have the best fit.

3. Results

The specimen extracted was identified as a male metastrongyloid nematode (Nematoda: Metastrongyloidea) of 14.4 mm long with caudal bursa and two spicules of 652 µm (Fig. 2). Based on the length of the spicules, *O. rostratus* and *A. abstrusus* were discarded, whereas this length is similar to that found in *Troglostrongylus* spp. and *G. parvalysans*.

Two 18S ribosomal RNA gene fragments, 340 and 665 bp, were obtained (MG870088 and MG870089, respectively). A BLAST search of GenBank showed the highest identity (99%) with *G. parvalysans* (GenBank Accession number JX975484) obtained from *Felis catus* from Chile. Both fragments were concatenated to perform the phylogenetic analysis, which also showed that the nematode observed in this study is most closely related to *G. parvalysans* (Fig. 3).

One week after surgery the fibrin deposits disappeared and the foci of chorioretinitis remained stable, but posterior synechiae were persistent, there was a presence of corneal edema in the area of the incision, and the individual showed incipient cataract. A local and oral treatment was performed for one month and two weeks respectively. Antiparasitic treatment was carried out with fipronil, (S)-methoprene, eprinomectin and praziquantel (Broadline spot-on® Merial solution). Subsequent explorations were positive, and no symptoms of uveitis reappeared, leaving the foci of chorioretinitis inactive, whereas remnants of posterior synechiae and incipient cataracts remained as sequelae of surgery. After 6 months, the cat is stable and without symptoms, waiting for cataract surgery.

4. Discussion

The distribution and importance of injuries produced by the Metastrongyloidea family of nematodes in domestic carnivores are well documented (Bowman et al., 2002). These parasites are frequently associated with pulmonary tissue, although some parasites stages are usually found in blood vessels. There are five of these parasites reported




Fig. 3. Bayesian analysis of metastrongyloid nematodes based on concatenated 18S sequences. The sequence obtained in this work is indicated in bold (TenGurt2017). *Nippostrongylus brasiliensis* was used as the outgroup. The HKY + G + I was selected as the best-fit model for the phylogenetic analysis. The analysis was carried out with $n_{gen} = 8 \times 10^6$ and the first 25% trees were discarded as burn-in. Posterior probabilities are noted on nodes.

in domestic cats, and *A. abstrusus* is the most common among them (Bowman et al., 2002; Brianti et al., 2013). The other four species are *G. paralyans*, *O. rostratus*, *Troglstrongylus brevior* and *Troglstrongylus subcrenatus*, which are sporadically reported (Bowman et al., 2002; Brianti et al., 2013). Prior studies of metastrongyloid species infecting cats have demonstrated the presence of *A. abstrusus*, *O. rostratus* and *Troglstrongylus* sp. in Spain (Jefferies et al., 2010).

The morphological and morphometric characteristics of the parasite analyzed in this study are similar to those described for *G. paralyans* (Muñoz et al., 2017) and molecular analyses confirmed this identity. *Gurltia paralyans*, first reported in the 1930s (Moroni et al., 2012), is considered a neglected feline neurological parasitosis (Muñoz et al., 2017). It is a neurotropic metastrongyloid nematode of domestic cats that is mainly found in the veins of the spinal cord subarachnoid space and parenchyma (Bowman et al., 2002). The parasite causes neurological pathologies, usually invades the leptomeningeal vasculature, causing diffuse meningomyelitis and thrombophlebitis (Bowman et al., 2002; Gomez et al., 2010; Mieres et al., 2013). Moroni et al. (2012) cited *G. paralyans* as a rare parasite, and provided new information on associated clinical and pathological findings in naturally infected domestic cats from southern Chile, where three cases of neurological diseases were reported. However, no previous data are available on the presence of *G. paralyans* as ectopic parasite. The presence of ectopic parasites is often related to immunosuppression, but in this case, normal values were obtained in all the analyses carried out, showing that it was apparently an immunocompetent cat.

Gurltia paralyans has been only found in South America, mainly in Chile and Argentina (Gomez et al., 2010; Guerrero et al., 2011), although the parasite has also been sporadically reported in Uruguay, Colombia and Brazil (Alzate et al., 2011; Rivero et al., 2011; Togni et al., 2012). The prevalence of the parasite in these regions is unknown and infection may be underdiagnosed. Therefore, this would be the first report of *G. paralyans* out of South America.

Domestic cats are most likely infected by *G. paralyans* by ingesting intermediate (slugs) or paratenic hosts (lizards, rodents, and birds). However, the exact life cycle and epidemiology of the parasite remains unclear (Moroni et al., 2012). Co-infection with *A. abstrusus* has been also reported by Mieres et al. (2013).

This finding indicates that veterinarians in Tenerife should consider *G. paralyans* as a possible cause of neurological and ocular disorders in cats, as it has been found in a cat which had never travelled out of Tenerife since it was rescued. The presence of *G. paralyans* in Tenerife could be due to the introduction of foreign domestic cats from South America to the island, brought by their owners.

5. Conclusion

This is the first report of ocular infection caused by *Gurltia paralyans*, as well as the first report of the nematode out of South America.

Appendix A. Supplementary data

Supplementary material related to this article can be found, in the online version, at doi:<https://doi.org/10.1016/j.vetpar.2018.03.027>.

References

- Alzate, G., Aranzazu, D., Alzate, A., Chaparro, J., 2011. Domestic cat paraplegia compatible with *Gurltia paralyans* nematode. First cases reported in Colombia. Rev. Colomb. Cienc. Pec. 24, 663–669.
- Anderson, R.C., 2000. Nematode parasites of vertebrates. Their Development and Transmission, 2nd ed. CABI Publishing, Guilford, UK, pp. 404–407.
- Bowman, D., Hendrix, C.M., Lindsay, D.S., Barr, S., 2002. Metastrongyloidea. In: Bowman, D. (Ed.), Feline Clinical Parasitology. Iowa State University Press, Iowa, pp. 272–273.
- Brianti, E., Gaglio, G., Giannetto, S., Annoscia, G., Latrofa, M.S., Dantas-Torres, F., Traversa, D., Otranto, D., 2012. *Troglstrongylus brevior* and *Troglstrongylus subcrenatus* (Strongylida: Crenosomatidae) as agents of broncho-pulmonary infestation in domestic cats. Parasites Vector 5, 178.
- Brianti, E., Gaglio, G., Napoli, E., Falsone, L., Giannetto, S., Latrofa, M.S., Giannelli, A., Dantas-Torres, F., Otranto, D., 2013. Evidence for direct transmission of the cat lungworm *Troglstrongylus brevior* (Strongylida: Crenosomatidae). Parasitology 140 (7), 821–824.
- Brianti, E., Giannetto, S., Dantas-Torres, F., Otranto, D., 2014. Lung worms of the genus *Troglstrongylus* (Strongylida: Crenosomatidae): neglected parasites for domestic cats. Vet. Parasitol. 202, 104–112.
- Darriba, D., Taboada, G.L., Doallo, R., Posada, D., 2012. jModelTest 2: more models, new heuristics and parallel computing. Nat. Methods 9 772–772.
- Glass, E.N., Cometta, A.M., De Lahunta, A., Center, S.A., Kent, M., 1998. Clinical and clinicopathologic features in 11 cats with *Cuterebra* larvae myiasis of the central nervous system. J. Vet. Intern. Med. 12 (5), 365–368.
- Gomez, M., Mieres, M., Moroni, M., Mora, A., Barrios, N., Simeone, C., Lindsay, D.S., 2010. Meningomyelitis due to nematode infection in four cats. Vet. Parasitol. 170, 327–330.
- Guerrero, I., Paludi, A., Saumell, L., 2011. Primera descripción en Argentina de *Gurltia paralyans* en un felino domestico. Tesina MV. Universidad del Centro de la Prov. Buenos Aires, Tandil, Argentina.
- Harris, B.P., Miller, P.E., Bloss, J.R., Pelliteri, P.J., 2000. Ophthalmomyiasis interna anterior associated with *Cuterebra* spp. in a cat. J. Am. Vet. Med. Assoc. 216, 352–355.
- Jefferies, R., Vrhovec, M.G., Wallner, N., Catalan, D.R., 2010. *Aelurostrongylus abstrusus* and *Troglstrongylus* sp. (Nematoda: Metastrongyloidea) infections in cats inhabiting Ibiza, Spain. Vet. Parasitol. 173 (3–4), 344–348.
- Labelle, A.L., Daniels, J.B., Dix, M., Labelle, P., 2011. *Onchocerca lupi* causing ocular disease in two cats. Vet. Ophthalmol. 14, 105–110.
- López, C., Clemente, S., Almeida, C., Brito, A., Hernández, M., 2015. A genetic approach to the origin of *Millepora* sp. in the eastern Atlantic. Coral Reefs 34 (2), 631–638.
- Mieres, M., Gomez, M.A., Lillo, C., Rojas, M.A., Moroni, M., Muñoz, P., Acosta-Jamett, G., Wiegand, R., 2013. Clinical, imaging and pathologic characteristics of *Gurltia*

- paralysans* myelopathy in domestic cats from Chile. Vet. Radiol. Ultrasound 54 (3), 237–244.
- Moroni, M., Muñoz, P., Gómez, M., Mieres, M., Rojas, M., Lillo, C., Aguirrea, F., Acosta-Jamett, G., Kaiser, M., Lindsay, D.S., 2012. *Gurltia paralysans* (Wolffhügel, 1933): description of adults and additional case reports of neurological diseases in three domestic cats from southern Chile. Vet. Parasitol. 184, 377–380.
- Motta, B., Nägeli, F., Nägeli, C., Solari-Basano, F., Schiessl, B., Deplazes, P., Schnyder, M., 2014. Epidemiology of the eye worm *Thelazia callipaeda* in cats from southern Switzerland. Vet. Parasitol. 203 (3–4), 287–293.
- Muñoz, P., Hirzmann, J., Rodríguez, E., Moroni, M., Taubert, A., Gibbons, L., Hermosilla, C., Gómez, M., 2017. Redescription and first molecular characterization of the little known feline neurotropic nematode *Gurltia paralysans* (Nematoda: Metastrongyloidea). Vet. Parasitol. Reg. Stud. Rep. 10, 119–125.
- Otranto, D., Traversa, D., 2005. *Thelazia* eyeworm: an original endo- and ecto-parasitic nematode. Trends Parasitol. 21 (1), 1–4.
- Rivero, R., Matto, C., Adrien, M., Nan, F., Bell, T., Gardiner, C., 2011. Parasite meningomyelitis in cats in Uruguay. Rev. Bras. Parasitol. Vet. 20, 259–261.
- Togni, M., Panziera, W., Souza, T.M., Oliveira, J.C., Mazzanti, A., Barros, C.S., Figuera, R.A., 2012. Aspectos epidemiológicos, clínicos e anatomopatológicos da Infecção por *Gurltia paralysans* em gatos. Pesqui. Vet. Bras. 33, 363–371.
- Williams, K.J., Summers, B.A., De Lahunta, A., 1998. Cerebrospinal cuterebriasis in cats and its association with feline ischemic encephalopathy. Vet. Pathol. 35 (5), 330–343.